

Jurnal Info Kesehatan

Vol. 22, No. 2, June 2024, pp. 244-258

P-ISSN 0216-504X, E-ISSN 2620-536X

DOI: [10.31965/infokes.Vol22.Iss2.1533](https://doi.org/10.31965/infokes.Vol22.Iss2.1533)

Journal homepage: <https://jurnal.poltekkeskupang.ac.id/index.php/infokes>



RESEARCH

Open Access

The Effects of Black Garlic on Ovarian Malondialdehyde, Oviduct Muscle, and Endometrial Arterioles in Smoke-Exposed Rats

Noni Fidya Ayu Anandasari^{1a*}, Novalia Kridayanti^{1b}, Ni Ketut Devy Kaspirayanti^{1c}, Tatit Nurseta^{2d}, Tri Yudani Mardining Raras^{3e}, Husnul Khotimah^{4f}, Subandi Reksokusodo^{1,2g}, Kenty Wantri Anita^{5h}, Hendy Setyo Yudhanto⁵ⁱ

¹ Master Program of Midwifery, Faculty of Medicine, Universitas Brawijaya, Malang, East Java, Indonesia

² Department of Obstetrics and Gynecology, Faculty of Medicine, Universitas Brawijaya, Malang, East Java, Indonesia

³ Department of Biochemistry and Molecular Biology, Faculty of Medicine, Universitas Brawijaya, Malang, Indonesia

⁴ Faculty of Medical, Universitas Brawijaya, Malang, East Java, Indonesia

⁵ Department of Pathological Anatomy, Faculty of Medicine, Universitas Brawijaya, Malang, East Java, Indonesia

^a Email address: nonifidyaayu@gmail.com

^b Email address: novalia.kri@gmail.com

^c Email address: devykaspira@student.ub.ac.id

^d Email address: tns_obg.fk@ub.ac.id

^e Email address: daniraras@ub.ac.id

^f Email address: husnul_farmako.fk@ub.ac.id

^g Email address: desobg@gmail.com

^h Email address: kenty_wa@ub.ac.id

ⁱ Email address: hendy.setyo@ub.ac.id

Received: 22 May 2024

Revised: 11 June 2024

Accepted: 19 June 2024

Abstract

The effect of cigarette smoke exposure on reproductive health has been widely studied, showing various physiological disorders induced by free radicals and oxidative stress. This study aimed to assess the protective effect of ethanol extract of black garlic (*Allium sativum*) on some reproductive parameters of female rats *Rattus norvegicus* exposed to subacute cigarette smoke. A proper experimental method with a post-test-only control group design was used, involving 25 rats divided into five groups with three different doses of the extract. The rats were exposed to cigarette smoke and then treated for 28 days. Results showed a significant decrease in ovarian Malondialdehyde levels and increased fallopian tube smooth muscle thickness in the extract-treated group. In addition, black garlic extract successfully increased the number of endometrial arterioles in the group exposed to cigarette smoke and extract, in contrast to the group exposed to cigarette smoke only. This study concludes that black garlic extract has the potential to be a protective agent against oxidative damage in the reproductive system of rats exposed to cigarette smoke, with effectiveness that depends on the dose of extract given. Further studies should investigate the long-term effects and optimal dosing of black garlic extract in humans. Additionally, exploring the molecular mechanisms behind its protective properties could enhance its application in reproductive health management.

Keywords: Black Garlic Extract, Cigarette Smoke, Oviduct Muscle, Malondialdehyde Levels, Endometrial Arterioles.

*Corresponding Author:

Noni Fidya Ayu Anandasari

Master Program of Midwifery, Faculty of Medicine, Universitas Brawijaya, Malang, East Java, Indonesia

Email: nonifidyaayu@gmail.com



©The Author(s) 2024. This article is distributed under the terms of the Creative Commons Attribution 4.0 International License (<http://creativecommons.org/licenses/by/4.0/>), which permits unrestricted use, distribution, and reproduction in any medium, provided you give appropriate credit to the original author(s) and the source, provide a link to the Creative Commons license, and indicate if changes were made. The Creative Commons Public Domain Dedication waiver (<http://creativecommons.org/publicdomain/zero/1.0/>) applies to the data made available in this article, unless otherwise stated.

1. INTRODUCTION

Cigarette smoke has been globally recognized as one of the leading causes of many severe diseases and health complications. According to a study conducted (Widyanti *et al.*, 2020);(Rahma *et al.*, 2019), cigarette smoke contributes to an increased risk of cardiovascular disease, chronic lung disease, as well as various neurological disorders such as Alzheimer's and Parkinson's. In Indonesia, the prevalence of smokers has shown a significant increase from 2011 to 2021, with more than 70 million residents actively smoking, resulting in a large population of secondhand smoke exposure in homes and public spaces (GATS, 2021).

Secondhand smoke is known to be a major risk factor for numerous chronic diseases globally, such as heart disease, reproductive issues, and lung cancer (Widyanti *et al.*, 2020). Cigarette smoke, which contains more than 4800 chemicals, including free radicals, causes significant oxidative stress in the body, which can affect reproductive health, especially in women (Rahma *et al.*, 2019).

Exposure to cigarette smoke has been linked to reduced fertility and a higher likelihood of miscarriage and various pregnancy complications (Trofor *et al.*, 2018). This exposure has severe implications for reproductive health, including decreased pregnancy potential and a high risk of disorders of reproductive organs such as the ovaries and endometrium.

Studies (Ardiana, 2021) show that cigarette smoke can reduce the chances of pregnancy by 30%, disrupt the normal function of reproductive hormones, and induce oxidative stress that damages reproductive cells. Harmful substances in cigarette smoke, including nicotine and carbon monoxide, have been shown to interfere with the expression of hormone receptors such as estrogen and progesterone and growth factors such as VEGF, which are critical for endometrial and ovarian function (Park *et al.*, 2022).

These substances have been linked to various health issues, including cancer. Studies have shown that cigarette smoking is associated with an increased risk of ovarian cancer (Faber *et al.*, 2013), and endometrial carcinoma (Felix *et al.*, 2014). Additionally, cigarette smoke exposure has been found to induce autophagy, dysregulate mitochondrial dynamics, and generate reactive oxygen species, leading to apoptosis and cell damage (Gannon *et al.*, 2013).

Furthermore, research has demonstrated that smoking cigarettes prevents bone-marrow-derived stem cells from being recruited to the uterus (Budani *et al.*, 2021), affecting uterine receptivity and potentially leading to fertility issues. It can also impact the expression of genes involved in the inflammatory response in the uterus, affecting processes essential for uterine growth and remodeling. Moreover, cigarette smoke has been implicated in causing damage to the ovary, inhibiting ovarian follicle growth, and affecting ovarian function (Aningsih *et al.*, 2020).

Recent studies have revealed that the prevalence of smoking in Indonesia is very high, with exposure to cigarette smoke occurring not only in the public environment but also at home, which increases the health risks of secondhand smoke, including women and children. The prevalence of smoking in Indonesia is very high. According to recent data, there are approximately 3,461,279 active female smokers in Indonesia. Additionally, the exposure to secondhand smoke is a significant issue, impacting both women and children in various environments, including homes and public places (Sala & Gotti, 2023; Tobacco Atlas, 2024; World Health Organization, 2024). The damage that secondhand smoke causes to the female reproductive system is a severe public health issue that requires effective intervention strategies.

Research in Indonesia shows an urgent need to address the health problems caused by cigarette smoke, especially among women who are at risk of infertility and other pregnancy complications due to oxidative stress and hormonal disruption induced by nicotine and other toxic substances in cigarette smoke (Kida *et al.*, 2021).

Faced with this problem, black garlic (*Allium sativum*) in ethanol extract may offer a potential solution. Black garlic, known for its high antioxidant content, "has shown potential in reducing oxidative damage induced by free radicals found in cigarette smoke" (Lu *et al.*, 2017). Previous studies have demonstrated that black garlic can improve antioxidant status and reduce biomarkers of oxidative damage in animal models and humans (Agustina *et al.*, 2020).

Therefore, this study aimed to evaluate the protective effect of ethanol extract of black garlic (*Allium sativum*) against the negative impact of cigarette smoke on the reproductive system of rats. Black garlic, a fermented form of garlic, is known to have a high concentration of antioxidants that can fight free radicals and potentially reduce oxidative damage to reproductive tissues (Lu *et al.*, 2017).

This study is expected to provide new insights into the potential use of black garlic as a mitigation strategy against the damaging effects of cigarette smoke, especially on Malondialdehyde levels, oviduct smooth muscle thickness, and the number of endometrial arterioles in animal models exposed to subacute cigarette smoke.

The results of this study are expected to provide new insights into the application of herbal medicine as a supporting therapy to protect reproductive organs from the adverse effects of cigarette smoke, offering a safer and more sustainable alternative therapy to reduce the health impacts caused by smoking habits that are still high in Indonesia.

2. RESEARCH METHOD

This research presents a unique laboratory experimental study that utilizes a 'post-test only control group' approach. The novelty lies in its focus on the direct effect of ethanol extract of black garlic on rats exposed to subacute cigarette smoke. The study was conducted at the Pharmacology Laboratory, Anatomical Pathology Laboratory Faculty of Medicine Brawijaya University, and Laboratorium Herbal Medika Batu City, from December 2024 to March 2024. The entire experimental procedure was approved by the Ethics Committee of the Faculty of Medicine, Brawijaya University, with ethical number 367/EC/KEPK-S2/11/2023.

The study population included 25 female Wistar strain white rats (*Rattus norvegicus*), aged 8-10 weeks with body weights between 150-200 grams, randomly selected into five groups of five animals each. The groups included one negative control group that was not exposed to cigarette smoke or extract, one positive control group that was only exposed to cigarette smoke, and three experimental groups that were exposed to cigarette smoke and given black garlic extract at doses of 50 mg/kgBW, 100 mg/kgBW, and 150 mg/kgBW. Each group was exposed to cigarette smoke for five minutes per session, two sessions per day for 28 days. The following is the division of the groups and the duration of exposure:

- 1) CN (Negative Control): This group was not exposed to cigarette smoke and was not given black garlic extract.
- 2) CP (Positive Control): Exposed to cigarette smoke twice a day for five minutes per session for 28 days without black garlic extract.
- 3) P1 (Treatment 1): Exposed to cigarette smoke twice a day for five minutes per session and given a dose of 50 mg/kgBW black garlic extract for 28 days.
- 4) P2 (Treatment 2): Exposed to cigarette smoke twice a day for five minutes per session and given a dose of 100 mg/kgBW black garlic extract for 28 days.
- 5) P3 (Treatment 3): Exposed to cigarette smoke twice a day for five minutes per session and given a 200 mg/kgBW dose of black garlic extract for 28 days.

The data were meticulously measured through analysis of Malondialdehyde levels with the Thiobarbituric Acid Reactive Substances (TBARS) method, ovarian smooth muscle thickness through histopathological analysis using Hematoxylin and Eosin (H&E) staining, and

the number of endometrial arterioles observed using light microscopy. To ensure the reliability of the findings, statistical analysis was performed using ANOVA to compare between groups, followed by Tukey's post hoc test if significant differences were found, with $p < 0.05$ as the significance limit.

Data presentation will include tables and graphs for straightforward interpretation of results and experimental flow charts and histological images to support the analysis. The tools used in this study include standard laboratory rat cages, a cigarette smoke machine that can control the dose and duration of exposure, ethanol extract of black garlic produced through the extraction of fermented black garlic with 70% ethanol, as well as a Thiobarbituric Acid Reactive Substances (TBARS) kit, microtome, Hematoxylin and Eosin (H&E) staining material, and microscope for histopathology analysis. Data were analyzed using statistical SPSS software to test for significant differences between groups.

3. RESULTS AND DISCUSSION

This study involved 25 female Wistar white rats divided into five study groups, each with five rats. The rats were exposed to two cigarette smoke cigarettes daily for 28 days and given different doses of black garlic extract.

Table 1. Normality and Homogeneousity Test of Malondialdehyde Level Data

Test	p-value	Description
Normality	0.207	Normal
Homogeneousity	0.159	Homogeneous

Table 1 shows that data normal and homogeneous distribution fulfills the prerequisites for further statistical analysis.

Table 2. Comparison of Test Results of Malondialdehyde Levels

Group	n	Mean \pm SD (μ M)	p-value
CN	5	1.157 \pm 0.60 ^a	0.000
CP	5	4.787 \pm 0.70 ^{cd}	
P1	5	2.674 \pm 1.70 ^a	
P2	5	3.980 \pm 0.27 ^{bc}	
P3	5	6.200 \pm 1.54 ^d	

Notes: CN: Negative control group, not exposed to cigarette smoke. CP: Positive control group, only exposed to cigarette smoke. P1, P2, P3: Groups exposed to cigarette smoke were given 50, 100, and 200 mg/kgBW of black garlic extract, respectively. p-value < 0.05 indicates a significant difference.

Table 2, One-way ANOVA analysis showed significant differences in Malondialdehyde levels between the control and treatment groups, with the highest levels in the group receiving the most significant black garlic dose (P3). Figure 1 shows the difference in mean Malondialdehyde levels between the unexposed, cigarette smoke-exposed, and cigarette smoke-exposed groups treated with black garlic extract.

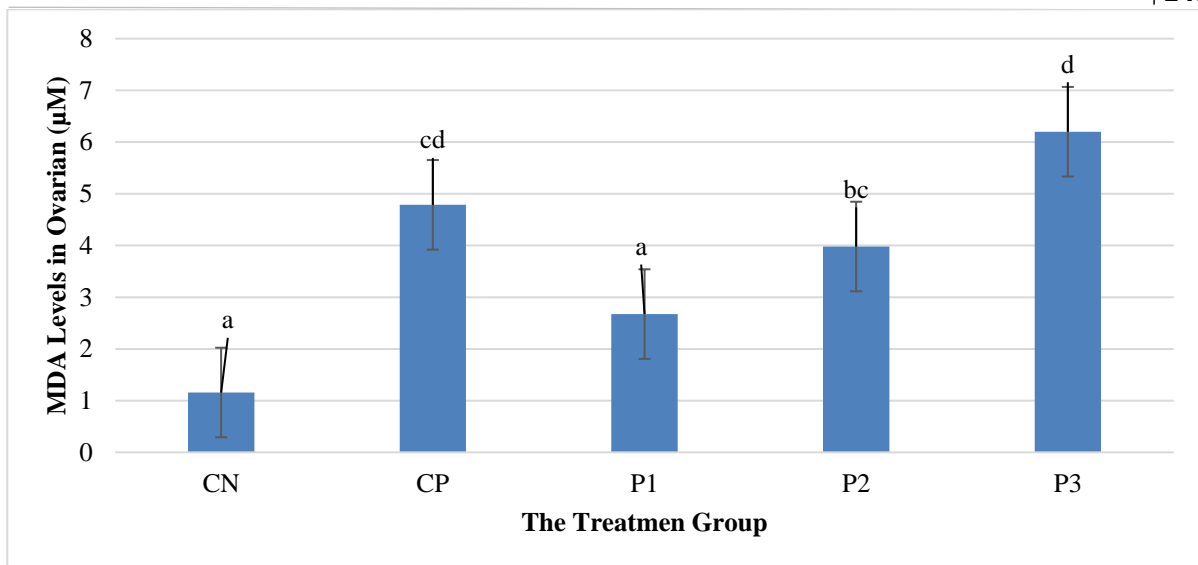


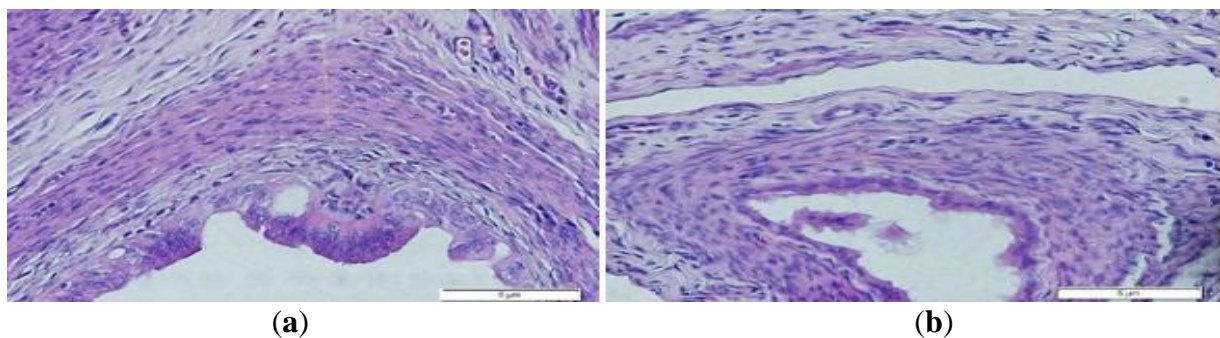
Figure 1. Malondialdehyde Levels

We divided the female *Rattus norvegicus* rats into several groups for our study. The first group (CN) was not exposed to any external factors. The second group (CP) was exposed to cigarette smoke. The third, fourth, and fifth groups (P1, P2, and P3) were also exposed to cigarette smoke, but in addition, they were given black garlic extract at doses of 50, 100, and 200 mg/kgBW, respectively. We then measured the mean ovarian Malondialdehyde levels in each group.

The results showed that black garlic extract could reduce Malondialdehyde levels at low doses (50 mg/kgBW). However, increased Malondialdehyde levels occurred at higher doses, suggesting a potential prooxidative effect at higher doses. These measurements suggest that black garlic extract at a specific dose can reduce cigarette smoke-induced oxidative damage in rat ovaries; however, increasing the dose above a certain threshold can increase Malondialdehyde levels, indicating the importance of proper dosing in the therapeutic application of this extract.

Effects of Black Garlic (*Allium sativum*) Ethanol Extract on Oviduct Smooth Muscle Thickness *Rattus norvegicus* Exposed to Subacute Cigarette Smoke

This study involved 25 female Wistar white rats divided into five research groups, each with five rats. The study lasted for 28 days in the pharmacology laboratory to measure the effect of black garlic extract on the thickness of fallopian tube smooth muscle in rats exposed to subacute cigarette smoke. Observations were made using an Olympus BX53 microscope with 400x magnification and counted in 5 fields of view.



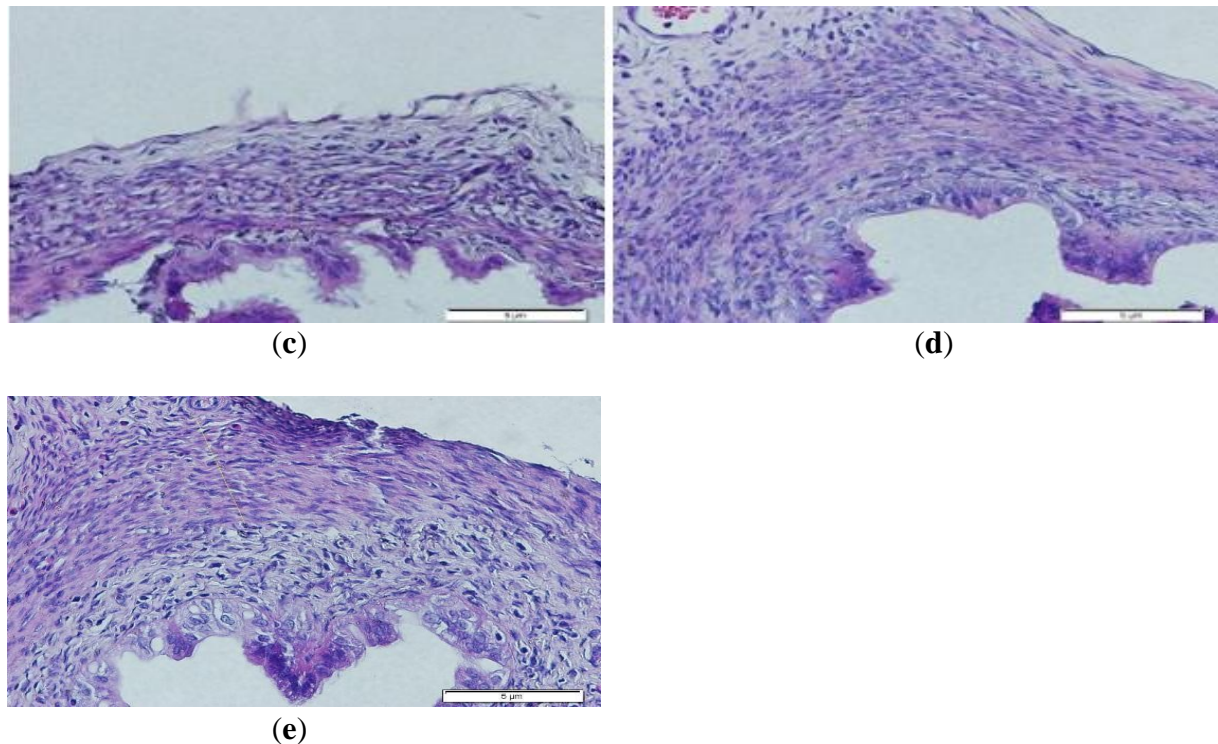


Figure 2. (a) Negative Control Group CN (-); (b) Positive Control Group CP (+); (c) Treatment Group 1 (Cigarette smoke exposure and dose of 50 mg/Kg/BW); (d) Treatment Group 2 (Cigarette smoke exposure and dose of 100mg/kg/BW; (e) Treatment Group 3 (Cigarette smoke exposure and dose of 200mg/kg/BW).

Table 3. Normality and Homogeneity Test of Fallopian Tube Smooth Muscle Thickness Data

Test	p-value	Description
Shapiro-Wilk Normality Test	0.715	Normal
Levene Homogeneity Test	0.087	Homogeneous

Table 3 shows that fallopian tube smooth muscle thickness data were normally distributed and homogeneous, fulfilling the prerequisites for further statistical analysis.

Table 4. One-Way Anova Test of Fallopian Tube Smooth Muscle Layer Thickness

Group	n	Mean \pm SD	p-value
CN	5	6.74160 \pm 1.635602 b	0.002
CP	5	4.08940 \pm 0.256373 a	
P1	5	5.78380 \pm 0.261336 b	
P2	5	5.90960 \pm 0.893802 b	
P3	5	6.17360 \pm 0.511684 b	

Notes: CN: Negative control group, not exposed to cigarette smoke. CP: Positive control group, only exposed to cigarette smoke. P1, P2, P3: Groups exposed to cigarette smoke and given black garlic extract, respectively, 50, 100, and 200 mg/kgBW. p-value <0.05 indicates a significant difference.

The administration of black garlic extract significantly increased the thickness of the smooth muscle layer, with a significant difference at a dose of 50 mg/kg/BW compared to the positive control.

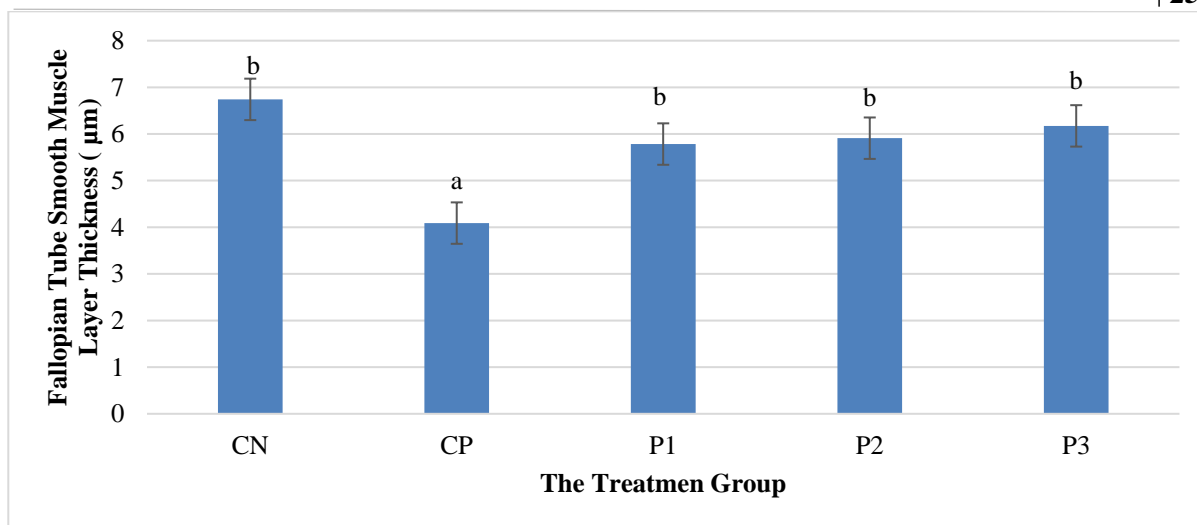


Figure 3. Effect of Black Garlic Extract on Increasing the Thickness of the Smooth Muscle Layer of Fallopian Tubes of White Rats Exposed to Cigarette Smoke.

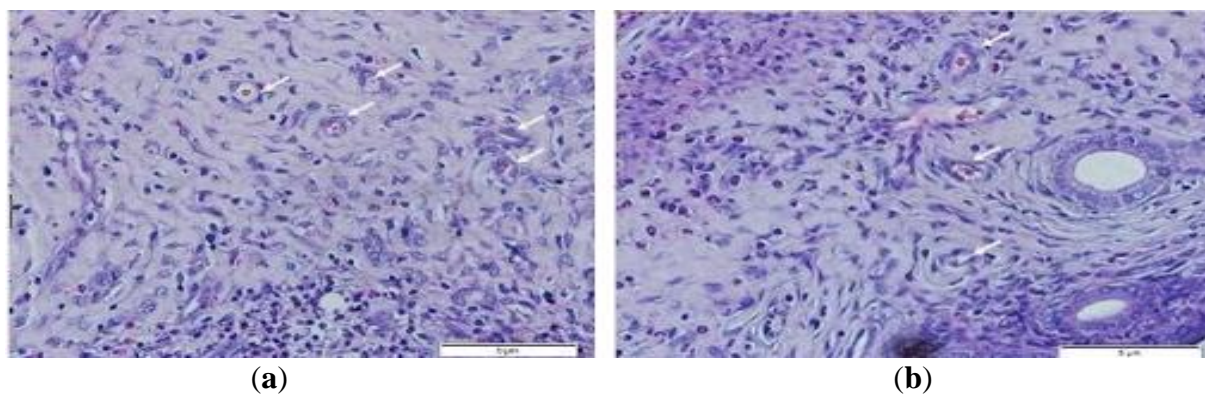
CN: control negative without exposure to cigarette smoke and administration of black garlic extract; CP: control positif exposed to cigarette smoke and without administration of black garlic extract; P1: exposed to cigarette smoke and given 50 mg/kgBW black garlic extract; P2: exposed to cigarette smoke and given 100 mg/kgBW black garlic extract; P3: exposed to cigarette smoke mg/gBW and given 200 mg/kgBW black garlic extract.

Figure 3 shows the fallopian tube smooth muscle thickness in groups exposed to cigarette smoke and those given black garlic extract. The increase in the thickness of the smooth muscle layer is most significant at low doses of extract.

This analysis indicates that black garlic extract can reduce the adverse effects of cigarette smoke exposure on the thickness of the fallopian tube smooth muscle, especially at a dose of 50 mg/kg/BW. These results confirm the potential of black garlic extract as a protective agent against tissue damage due to cigarette smoke exposure.

Effects of Black Garlic (*Allium sativum*) Ethanol Extract on Endometrial Arterioles Count in *Rattus Norvegicus* Exposed to Subacute Cigarette Smoke

This study used female Wistar rats divided into control and treatment groups with exposure to cigarette smoke and different doses of black garlic extract (50 mg/kg, 100 mg/kg, and 200 mg/kg). Observations were made using an Olympus BX53 light microscope, with 400x magnification, to measure the effect on the number of endometrial arterioles.



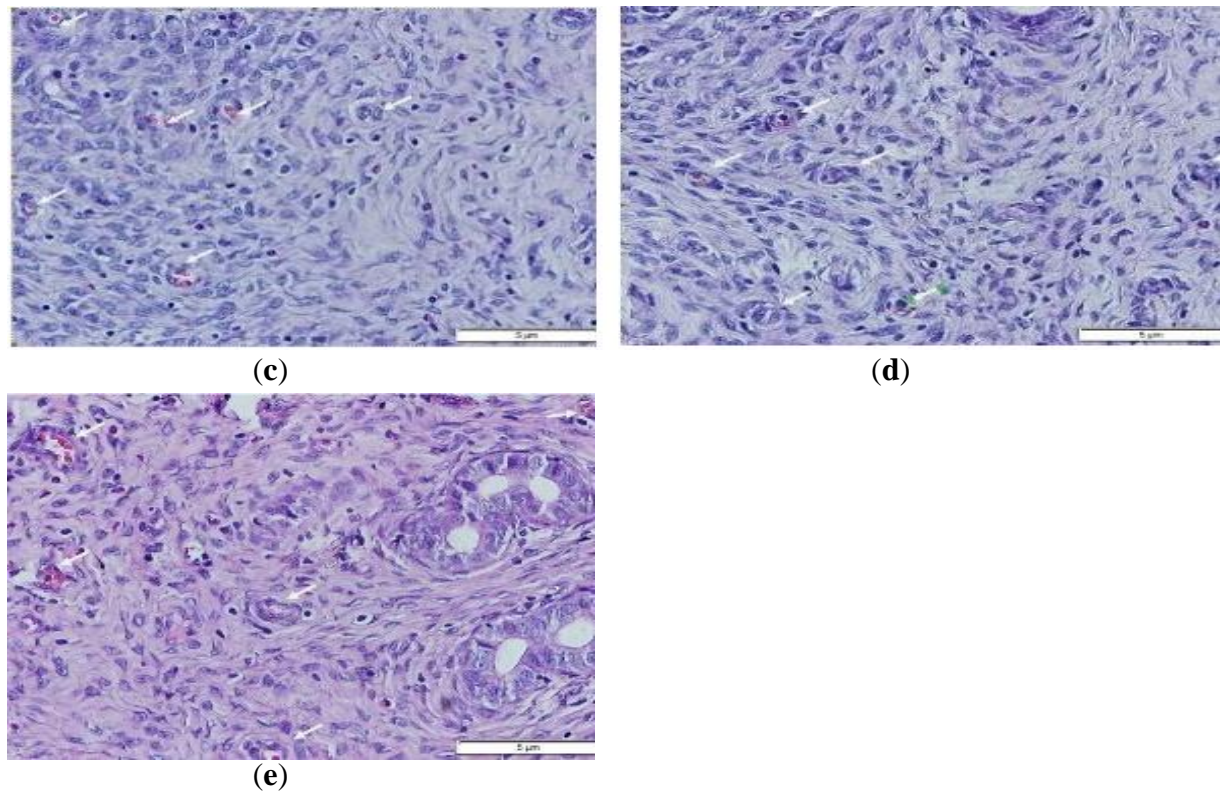


Figure 4. Arrows indicate spiral arterioles in rat endometrium with round tissue shape, with tunica intima, tunica media, and adventitia. (a) negative control group/no treatment; (b) positive control group/exposed to cigarette smoke; (c) treatment group 1 with cigarette smoke and black garlic 50 mg/kgBW; (d) treatment group with cigarette smoke and black garlic 100 mg/kgBW; (e) treatment group 3 with cigarette smoke and black garlic 200 mg/kgBW).

Table 5. Normality and Homogeneity Test of the Number of Endometrial Arterioles

Test	p-value	Description
Normality	0.972	Normal
Homogeneousitas	0.149	Homogeneous

Table 5 shows that the test results show that the data is usually distributed and Homogeneous, which allows further statistical analysis using the One Way ANOVA test.

Table 6. Comparison Test Results of The Number of Endometrial

Group	n	Mean \pm SD	p-value
CN	5	5.24 \pm 1.10 ^b	0.000
CP	5	2.20 \pm 0.38 ^a	
P1	5	5.12 \pm 1.06 ^b	
P2	5	4.24 \pm 0.49 ^b	
P3	5	3.76 \pm 0.72 ^b	

Different notations (a,b) give significant meaning to the mean \pm sd obtained (p-value $<$ α = 0.05), which means that there is a significant difference, and if the notation makes different letters (p-value $>$ α = 0.05), there is no significant difference in the HS post hoc test. Statistical analysis showed significant differences in the number of arterioles between the control and treatment groups, with a significant increase in the group treated with black garlic extract, especially at the lowest dose (50 mg/kg).

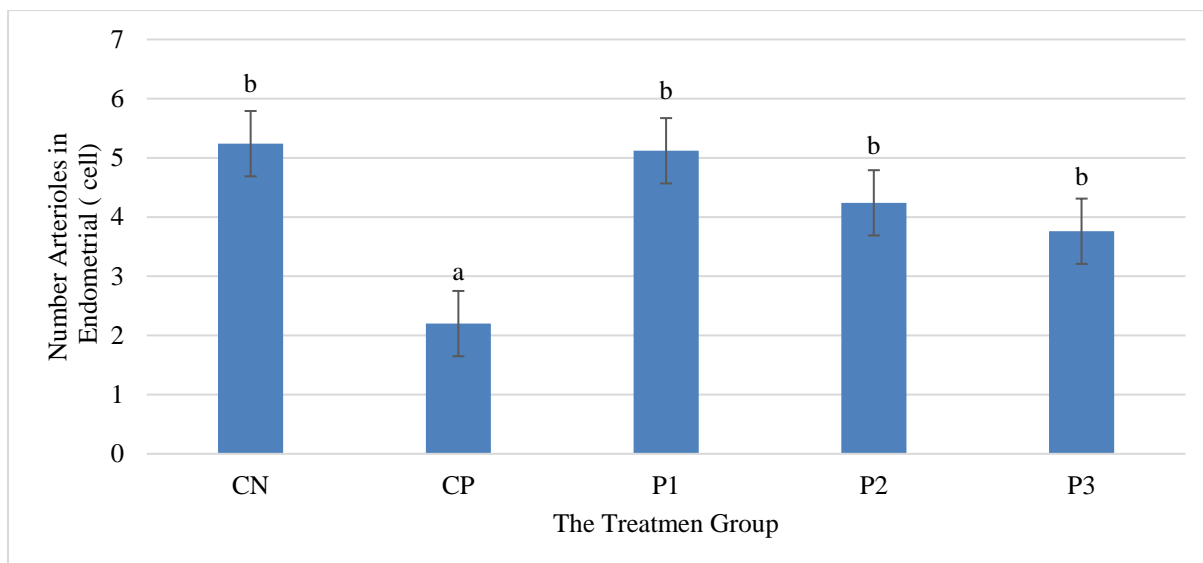


Figure 5. Number of Endometrial Arterioles

Different notations (a,b) give significant meaning to the mean \pm sd obtained (p -value $< \alpha = 0.05$), which means that there is a significant difference, and if the notation makes different letters (p -value $> \alpha = 0.05$), there is no significant difference in the HS post hoc test. Statistical analysis showed significant differences in the number of arterioles between the control and treatment groups, with a significant increase in the group treated with black garlic extract, especially at the lowest dose (50 mg/kg).

Figure 5 shows the mean number of endometrial arterioles in the negative control group, positive control group (exposed to cigarette smoke two cigarettes/day), P1 (exposed to cigarette smoke + BG 50 mg/kg/BW), P2 (exposed to cigarette smoke + BG 100 mg/kg/BW), P3 (exposed to cigarette smoke + BG 200 mg/kg/BW). The mean \pm sd obtained (p -value $< \alpha = 0.05$) can mean that there is a significant difference, and if (p -value $> \alpha = 0.05$), then there is no significant difference. This shows an increase in the number of arterioles in the group given black garlic extract, showing a protective effect against damage due to exposure to cigarette smoke.

Microscopic observations revealed that the arterioles in the group given black garlic extract showed a more preserved structure than those exposed to cigarette smoke in the positive control group. The group with a dose of 50 mg/kgBW of black garlic showed the highest number of arterioles, indicating the strongest positive effect against cigarette smoke damage.

These observations suggest that black garlic extract is potentially a protective agent against endometrial arteriolar damage caused by cigarette smoke exposure, with the most significant effect seen at a dose of 50 mg/kgBW.

DISCUSSION

Effects of Black Garlic (*Allium sativum*) Ethanol Extract on Malondialdehyde Levels in *Rattus Norvegicus* Exposed to Subacute Cigarette Smoke

Cigarette smoke exposure was shown to increase Malondialdehyde levels in *Rattus norvegicus*, indicating increased oxidative stress due to free radical activity derived from toxic substances in cigarette smoke (Aningsih *et al.*, 2020). Higher Malondialdehyde levels in groups exposed to cigarette smoke confirm the role of cigarette smoke in inducing lipid peroxidation

that has the potential to cause damage to cell membranes (Kole *et al.*, 2020);(Ningrum *et al.*, 2021).

Administering black garlic extract at a dose of 50 mg/kgBW led to a notable reduction in Malondialdehyde levels, highlighting black garlic's protective properties against oxidative stress caused by cigarette smoke exposure (Tsai *et al.*, 2019). These results are consistent with the study (Tsai *et al.*, 2019) , which found that black garlic extract was able to reduce Malondialdehyde and inflammatory responses in an acute liver injury model in rats.

Interestingly, increasing the black garlic extract given to the P3 group (200 mg/kgBW) did not provide a better protective effect; instead, it tended to show higher Malondialdehyde levels than the group with lower doses. This may indicate the existence of an optimal dose limit of black garlic extract in reducing oxidative stress, where higher doses can potentially induce pro-oxidative effects or toxicity by the thoughts expressed (Dutta *et al.*, 2021);(Gorrini *et al.*, 2013);(Penke *et al.*, 2017) regarding the potential toxicity of active components at high doses (Marengo *et al.*, 2016).

Furthermore, the decrease in Malondialdehyde levels at low doses (50 mg/kgBW) reflects the potential of black garlic in increasing the body's intrinsic antioxidant capacity through various mechanisms, including increased antioxidant enzyme activity and modulation of oxidative stress, as demonstrated (Oktari *et al.*, 2020);(Djedjibegovic *et al.*, 2020). Active components of black garlic such as S-Allylcysteine (SAC) play an important role in this process, given that SAC is known to have strong antioxidant effects. The differences in results between studies regarding the effectiveness of black garlic doses in reducing Malondialdehyde levels could be due to variations in extraction methods, experimental conditions, and the type and biological condition of the study subjects. This underscores the importance of standardizing research conditions and carefully considering the dose selection.

Effects of Black Garlic (*Allium sativum*) Ethanol Extract on Oviduct Smooth Muscle Thickness *Rattus norvegicus* Exposed to Subacute Cigarette Smoke

This study showed that exposure to cigarette smoke caused a decrease in fallopian tube smooth muscle thickness, which the administration of black garlic extract significantly increased. This decrease can be explained by the impact of cigarette smoke that induces oxidative stress and damages the structural integrity of smooth muscle tissue, as shown by the decrease in muscle thickness in the control group exposed to cigarette smoke (Lee *et al.*, 2017);(Kimura *et al.*, 2017).

The increase in smooth muscle thickness in the group given black garlic indicates the protective effect of bioactive compounds in black garlic against cigarette smoke-induced damage (Lu *et al.*, 2017). Black garlic, which undergoes a fermentation process, contains high concentrations of antioxidant compounds such as S-allyl cysteine (SAC), which are effective in neutralizing free radicals generated from cigarette smoke (Felix *et al.*, 2014).

These results are consistent with a study (Lu *et al.*, 2017), which showed that black garlic extract can reduce oxidative stress and increase antioxidant enzyme levels, reducing inflammation associated with oxidative damage to tissues (Lee *et al.*, 2017). By inhibiting inflammatory pathways and strengthening the body's antioxidant capacity, black garlic extract promotes the maintenance of smooth muscle tissue structure and avoids degradation caused by free radicals (Tsai *et al.*, 2019).

In the context of molecular mechanisms (Dampati & Veronica, 2020) explained that cigarette smoke can interfere with hormone signals necessary for the normal function of the fallopian tubes through disruptive endocrine mechanisms (Recinella *et al.*, 2021). Black garlic extract may mitigate some of these effects by affecting the expression of hormone receptors

and proteins involved in muscle contractility, which might help maintain fallopian tube smooth muscle function in the face of oxidative stress (Szumilas *et al.*, 2020).

Black garlic has metabolic and anti-inflammatory effects in chronic disease models, indicating that black garlic administration not only affects tissue structure but also has the potential to improve physiological functions in the reproductive system affected by exposure to environmental toxins such as cigarette smoke (Amor *et al.*, 2019).

This study underscores the potential of black garlic extract as a therapeutic agent in preventing tissue damage induced by cigarette smoke. These findings may enrich our understanding of the interactions between nutrition and oxidative stress and support the development of nature-based therapeutic approaches in dealing with oxidative damage in the reproductive system.

The absence of articles from Indonesian researchers in this discussion does not imply that black garlic is unavailable in Indonesia or that it lacks research interest there. Black garlic, known for its numerous health benefits, is indeed available and used in Indonesia. The use of international references, such as those cited from Lee, Kimura, and Lu, highlights studies that may have broader recognition or specific findings pertinent to this research.

Black garlic is gaining popularity in Indonesia, both as a culinary ingredient and for its medicinal properties. Indonesian researchers and consumers are increasingly aware of its benefits, and local studies are emerging that focus on its health effects. The fermentation process to produce black garlic, which enhances its antioxidant properties, is well understood and practiced in Indonesia.

However, the inclusion of international articles in this discussion aims to leverage widely recognized studies to support the findings and ensure the study's credibility. Future research could benefit from incorporating more local studies to reflect regional usage and research advancements in Indonesia, thereby providing a comprehensive view of black garlic's impact based on both global and local perspectives.

Effects of Black Garlic (*Allium sativum*) Ethanol Extract on Endometrial Arterioles Count in *Rattus Norvegicus* Exposed to Subacute Cigarette Smoke

This study highlights the significant impact of black garlic extract in increasing the number of endometrial arterioles in rats exposed to subacute cigarette smoke. Cigarette smoke contains compounds that can cause oxidative reactions and inflammation in various body tissues, including the endometrium, which in this study led to a decrease in the number of endometrial arterioles (Oktari *et al.*, 2020).

In the context of this study, black garlic extract, which is rich in antioxidants, plays a vital role in protecting endometrial tissue from cigarette smoke-induced oxidative damage. The increase in the number of arterioles observed in the treated groups, especially at the dose of 50 mg/kgBW, suggests that black garlic has a protective effect on the microvascular structure of the endometrium.

The mechanism behind this effect could be explained through the role of black garlic extract in modulating the VEGF and FGF pathways, which are critical factors in angiogenesis, as revealed (Guo *et al.*, 2021). These two growth factors are responsible for endothelial cell proliferation and migration, which are the initial steps in angiogenesis. Research by Delbandi *et al.* (2020) also showed that black garlic extract supports the formation of new blood vessels by facilitating the migration of these cells, which might explain the increased number of arterioles found in this study.

Administration of black garlic extract is also associated with increased antioxidant activity and reduced oxidative stress in endometrial tissue, as shown (Hoyt *et al.*, 2003), who

found that the extract increased enzymes such as SOD, catalase, and GPx. This is relevant as high oxidative stress is associated with vascular damage and angiogenesis dysfunction.

In addition, studies (Wei *et al.*, 2017) highlighted the potential of black garlic as an anti-inflammatory and anti-cancer agent, showing that it can inhibit angiogenesis in the context of cancer cells, yet in the context of inflammation and damage by cigarette smoke, this extract supports healthy angiogenesis processes (Holbrook, 2016).

This discovery significantly contributes to the development of science, particularly in understanding the interaction between functional food components such as black garlic and biological processes such as angiogenesis under pathological conditions. It also paves the way for the development of therapeutic strategies that can reduce the risk of vascular diseases induced by environmental factors such as cigarette smoke.

In the context of enrichment and technological development for society, these results support using black garlic in the diet as a preventive and therapeutic strategy to ameliorate vascular damage and support reproductive health, particularly in communities exposed to cigarette smoke or other pollutants.

4. CONCLUSION

This study concludes that black garlic extract has the potential to be a protective agent against oxidative damage in the reproductive system of rats exposed to cigarette smoke, with effectiveness that depends on the dose of extract given. Further studies should investigate the long-term effects and optimal dosing of black garlic extract in humans. Additionally, exploring the molecular mechanisms behind its protective properties could enhance its application in reproductive health management.

REFERENCES

- Agustina, E., Andiarna, F., & Hidayati, I. (2020). Uji Aktivitas Antioksidan Ekstrak Bawang Hitam (Black Garlic) Dengan Variasi Lama Pemanasan. *Al-Kauniah: Jurnal Biologi*, *13*(1), 39–50. <https://doi.org/10.15408/kauniah.v13i1.12114>
- Amor, S., González-Hedström, D., Martín-Carro, B., Inarejos-García, A. M., Almodóvar, P., Prodanov, M., García-Villalón, A. L., & García, M. G. (2019). Beneficial effects of an aged black garlic extract in the metabolic and vascular alterations induced by a high fat/sucrose diet in male rats. *Nutrients*, *11*(1). <https://doi.org/10.3390/nu11010153>
- Aningsih, B. S. D., Sujuti, H., Mustofa, E., & Ratnawati, R. (2020). Anthocyanins from *Ipomoea batatas* L. Effect on ovarian malondialdehyde and 17 β -estradiol in rats exposed cigarette smoke. *Russian Open Medical Journal*, *9*(3), 1–5. <https://doi.org/10.15275/rusomj.2020.0308>
- Ardiana, M. (2021). *Telaah Ilmiah Dan Patologi Paparan Asap Rokok Terhadap Penyakit Jantung*. Airlangga University Press.
- Budani, M. C., Carletti, E., & Tiboni, G. M. (2021). In Vivo Cigarette Smoke Exposure to Examine the Expression of Genes Involved in the Inflammatory Response in the Mouse Uterus. *Current Protocols*, *1*(6), 1–9. <https://doi.org/10.1002/cpz1.172>
- Dampati, P. S., & Veronica, E. (2020). Potensi Ekstrak Bawang Hitam sebagai Tabir Surya terhadap Paparan Sinar Ultraviolet. *KELUWIH: Jurnal Kesehatan Dan Kedokteran*, *2*(1), 23–31. <https://doi.org/10.24123/kesdok.v2i1.3020>
- Delbandi, A. A., Mahmoudi, M., Shervin, A., Heidari, S., Kolahdouz-Mohammadi, R., & Zarnani, A. H. (2020). Evaluation of apoptosis and angiogenesis in ectopic and eutopic stromal cells of patients with endometriosis compared to non-endometriotic controls. *BMC Women's Health*, *20*(1), 1–9. <https://doi.org/10.1186/s12905-019-0865-4>
- Djedjibegovic, J., Marjanovic, A., Panieri, E., & Saso, L. (2020). Ellagic Acid-Derived

- Urolithins as Modulators of Oxidative Stress. *Oxidative Medicine and Cellular Longevity*, 2020(Figure 1). <https://doi.org/10.1155/2020/5194508>
- Dutta, A., Dahiya, A., Prakash, A., & Agrawala, P. K. (2021). Acute toxicity of diallyl sulfide derived from *Allium sativum* (garlic) in mice and its possible mechanisms. *Phytomedicine Plus*, 1(3), 100084. <https://doi.org/10.1016/j.phyplu.2021.100084>
- Faber, M. T., Kjær, S. K., Dehlendorff, C., Chang-Claude, J., Andersen, K. K., Høgdall, E., Webb, P. M., Jordan, S. J., Rossing, M. A., Doherty, J. A., Lurie, G., Thompson, P. J., Carney, M. E., Goodman, M. T., Ness, R. B., Modugno, F., Edwards, R. P., Bunker, C. H., Goode, E. L., ... Jensen, A. (2013). Cigarette smoking and risk of ovarian cancer: A pooled analysis of 21 case-control studies. *Cancer Causes and Control*, 24(5), 989–1004. <https://doi.org/10.1007/s10552-013-0174-4>
- Felix, A. S., Yang, H. P., Gierach, G. L., Park, Y., & Brinton, L. A. (2014). Cigarette smoking and endometrial carcinoma risk: The role of effect modification and tumor heterogeneity. *Cancer Causes and Control*, 25(4), 479–489. <https://doi.org/10.1007/s10552-014-0350-1>
- Gannon, A. M., Stämpfli, M. R., & Foster, W. G. (2013). Cigarette smoke exposure elicits increased autophagy and dysregulation of mitochondrial dynamics in murine granulosa cells. *Biology of Reproduction*, 88(3), 1–11. <https://doi.org/10.1095/biolreprod.112.106617>
- GATS. (2021). Gats|Global Adult Tobacco Survey Fact Sheet Indonesia 2021 Gats Objectives. *Fact Sheet Indonesia*, 1–2.
- Gorrini, C., Harris, I. S., & Mak, T. W. (2013). Modulation of oxidative stress as an anticancer strategy. *Nature Reviews Drug Discovery*, 12(12), 931–947. <https://doi.org/10.1038/nrd4002>
- Guo, X., Yi, H., Li, T. C., Wang, Y., Wang, H., & Chen, X. (2021). Role of vascular endothelial growth factor (Vegf) in human embryo implantation: Clinical implications. *Biomolecules*, 11(2), 1–16. <https://doi.org/10.3390/biom11020253>
- Holbrook, B. D. (2016). The effects of nicotine on human fetal development. *Birth Defects Research Part C - Embryo Today: Reviews*, 108(2), 181–192. <https://doi.org/10.1002/bdrc.21128>
- Hoyt, J. C., Robbins, R. A., Habib, M., Springall, D. R., Buttery, L. D. K., Polak, J. M., & Barnes, P. J. (2003). Cigarette smoke decreases inducible nitric oxide synthase in lung epithelial cells. *Experimental Lung Research*, 29(1), 17–28. <https://doi.org/10.1080/01902140303759>
- Kida, N., Nishigaki, A., Kakita-Kobayashi, M., Tsubokura, H., Hashimoto, Y., Yoshida, A., Hisamatsu, Y., Tsuzuki-Nakao, T., Murata, H., & Okada, H. (2021). Exposure to cigarette smoke affects endometrial maturation including angiogenesis and decidualization. *Reproductive Medicine and Biology*, 20(1), 108–118. <https://doi.org/10.1002/rmb2.12360>
- Kimura, S., Tung, Y. C., Pan, M. H., Su, N. W., Lai, Y. J., & Cheng, K. C. (2017). Black garlic: A critical review of its production, bioactivity, and application. *Journal of Food and Drug Analysis*, 25(1), 62–70. <https://doi.org/10.1016/j.jfda.2016.11.003>
- Kole, E., Ozkan, S. O., Eraldemir, C., Akar, F. Y., Ozbek, S. K., Kole, M. C., Kum, T., & Filiz, P. C. (2020). Effects of melatonin on ovarian reserve in cigarette smoking: An experimental study. *Archives of Medical Science*, 16(6), 1376–1386. <https://doi.org/10.5114/AOMS.2019.89409>
- Lee, H. M., Kim, C. W., Hwang, K. A., Sung, J. H., Lee, J. K., & Choi, K. C. (2017). Cigarette smoke impaired maturation of ovarian follicles and normal growth of uterus inner wall

- of female wild-type and hypertensive rats. *Reproductive Toxicology*, 73, 232–240. <https://doi.org/10.1016/j.reprotox.2017.06.187>
- Lu, X., Li, N., Qiao, X., Qiu, Z., & Liu, P. (2017). Composition analysis and antioxidant properties of black garlic extract. *Journal of Food and Drug Analysis*, 25(2), 340–349. <https://doi.org/10.1016/j.jfda.2016.05.011>
- Marengo, B., Nitti, M., Furfaro, A. L., Colla, R., Ciucis, C. De, Marinari, U. M., Pronzato, M. A., Traverso, N., & Domenicotti, C. (2016). Redox homeostasis and cellular antioxidant systems: Crucial players in cancer growth and therapy. *Oxidative Medicine and Cellular Longevity*, 2016. <https://doi.org/10.1155/2016/6235641>
- Ningrum, A. G., Frety, E. E., Diah, I., Shabran, Z. H., Setiani, R. E., & Dewi, E. R. (2021). Antioxidant activity of purslane (*Portulaca oleracea* L.) leaf extract on the levels of ovarian oxidative stress and reproductive hormone in *rattus norvegicus* exposed to cigarette smoke. *Open Access Macedonian Journal of Medical Sciences*, 9(B), 1535–1540. <https://doi.org/10.3889/oamjms.2021.7081>
- Oktari, Kwartika, Azizah, Z., Chandra, B., & Asra, R. (2020). A Review: Antioxidant and Immunomodulator Effects of Black Garlic. *EAS Journal of Pharmacy and Pharmacology*, 2(6), 193–198. <https://doi.org/10.36349/easjpp.2020.v02i06.001>
- Park, S. R., Kim, S. K., Kim, S. R., Yu, W. J., Lee, S. J., & Lee, H. Y. (2022). Effects of smoking on the tissue regeneration-associated functions of human endometrial stem cells via a novel target gene SERPINB2. *Stem Cell Research and Therapy*, 13(1), 1–20. <https://doi.org/10.1186/s13287-022-03061-1>
- Penke, B., Fulop, L., Szucs, M., & Frecska, E. (2017). The Role of Sigma-1 Receptor, an Intracellular Chaperone in Neurodegenerative Diseases. *Current Neuropharmacology*, 16(1), 97–116. <https://doi.org/10.2174/1570159x15666170529104323>
- Rahma, F., Ardiaria, M., & Panunggal, B. (2019). Pengaruh Pemberian Ubi Jalar Ungu (*Ipomoea batatas* L. Poir) Terhadap Kadar Leukosit Total Tikus Wistar Jantan (*Rattus norvegicus*) Yang Dipapar Asap Rokok. *Journal of Nutrition College*, 8(2), 65. <https://doi.org/10.14710/jnc.v8i2.23815>
- Recinella, L., Chiavaroli, A., Masciulli, F., Frascchetti, C., Filippi, A., Cesa, S., Cairone, F., Gorica, E., De Leo, M., Braca, A., Martelli, A., Calderone, V., Orlando, G., Ferrante, C., Menghini, L., Di Simone, S. C., Veschi, S., Cama, A., Brunetti, L., & Leone, S. (2021). Protective effects induced by a hydroalcoholic *allium sativum* extract in isolated mouse heart. *Nutrients*, 13(7). <https://doi.org/10.3390/nu13072332>
- Sala, M., & Gotti, C. (2023). Electronic nicotine delivery systems (ENDS): A convenient means of smoking? *Pharmacological Research*, 195(June). <https://doi.org/10.1016/j.phrs.2023.106885>
- Szumilas, K., Szumilas, P., Grzywacz, A., & Wilk, A. (2020). The effects of e-cigarette vapor components on the morphology and function of the male and female reproductive systems: A systematic review. *International Journal of Environmental Research and Public Health*, 17(17), 1–13. <https://doi.org/10.3390/ijerph17176152>
- Tobacco Atlas. (2024). *Findings from the Third Tobacconomics Cigarette Tax Scorecard*. <https://tobaccoatlas.org/inadequate-tobacco-tax-policies-threaten-global-tobacco-control-progress/>
- Trofor, A. C., Papadakis, S., Lotrean, L. M., Radu-Loghin, C., Eremia, M., Mihaltan, F., Driezen, P., Kyriakos, C. N., Mons, U., Demjén, T., Nogueira, S. O., Fernández, E., Tountas, Y., Przewoźniak, K., McNeill, A., Fong, G. T., & Vardavas, C. I. (2018). Knowledge of the health risks of smoking and impact of cigarette warning labels among tobacco users in six European countries: Findings from the EUREST-PLUS ITC Europe Surveys. *Tobacco Induced Diseases*, 16(October), 1–13.

<https://doi.org/10.18332/tid/99542>

- Tsai, J. C., Chen, Y. A., Wu, J. T., Cheng, K. C., Lai, P. S., Liu, K. F., Lin, Y. K., Huang, Y. T., & Hsieh, C. W. (2019). Extracts from fermented black garlic exhibit a hepatoprotective effect on acute hepatic injury. *Molecules*, 24(6), 1–13. <https://doi.org/10.3390/molecules24061112>
- Wei, Z., Shan, Y., Tao, L., Liu, Y., Zhu, Z., Liu, Z., Wu, Y., Chen, W., Wang, A., & Lu, Y. (2017). Diallyl trisulfides, a natural histone deacetylase inhibitor, attenuate HIF-1 α synthesis, and decreases breast cancer metastasis. In *Molecular Carcinogenesis* (Vol. 56, Issue 10). <https://doi.org/10.1002/mc.22686>
- Widyanti, A. S., Ardiaria, M., & Widyastuti, N. (2020). Pengaruh pemberian ubi jalar ungu (*Ipomoea batatas* L.Poir) terhadap kadar superoksida dismutase (SOD) tikus wistar jantan (*Rattus Norvegicus*) yang dipapar asap rokok. *Jurnal Gizi Indonesia*, 8(1), 45. <https://doi.org/10.14710/jgi.8.1.45-50>
- World Health Organization. (2024). *Tobacco: E-cigarettes*. World Health Organization. <https://www.who.int/news-room/questions-and-answers/item/tobacco-e-cigarettes#:~:text=Are ENDS addictive%3F,can reach dangerously high levels>